

## Review on introduction of glaucoma and herbal products for treatment of glaucoma

Miss. Vaishnavi Vilas Pund.

Prof. Priyanka N. Shinde

*Principal-Dr. Megha Salve mam*

*Department of bachelor of pharmacy*

*Shivajirao Pawar College of Pharmacy, Pachegaon. Ahmednagar-413725*

Date of Submission: 09-11-2023

Date of Acceptance: 24-11-2023

### Abstract –

Glaucoma is an incurable eye disease that causes slowly progressive degeneration of the retina. It is not possible to fully recover, but if diagnosed early, progression can be controlled. Unfortunately, due to the lack of obvious symptoms in the early stages, early diagnosis is rare. Glaucoma must be detected early because late diagnosis can lead to permanent vision loss.

Intraocular pressure (IOP) is currently the only modifiable risk factor that slows or stops disease progression ; However, glaucomatous lesions , persist in almost 50% of patients , despite a significant reduction in intraocular pressure. Multiple , studies have examined , non-IOP risk factors that contribute to glaucoma progression, as well as , interventions that can prevent or delay glaucomatous neurodegeneration and , maintain vision throughout life, , regardless of intraocular pressure. A staggering , experimental studies have demonstrated the effectiveness of , neuroprotections against glaucoma, and , clinical trials are underway attempting to provide convincing evidence of the effectiveness of , of these interventions.

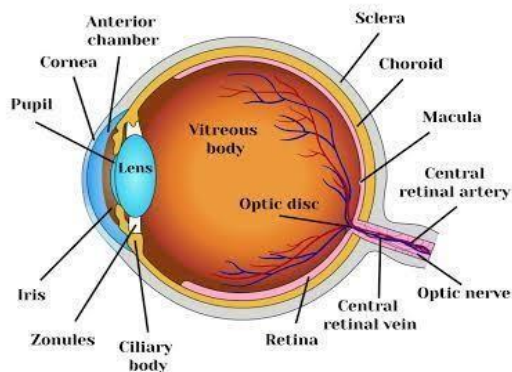
It Is the second leading cause of blindness worldwide. The article provides a brief overview of this disease and the options for its pharmacological treatment.[1,2,3]

**Keywords-** Glaucoma, Intra ocular pressure , Visual field loss, Herbal medicines.

### I. Introduction-

Glaucoma is the leading cause of incurable blindness worldwide. In 2010, an estimated 60.5 million people had glaucoma. In 2020, this number increased to 79.6 million. Glaucoma is more common in people of African and Hispanic descent [3,4], and glaucoma patients may be asymptomatic for many years, causing these measurements to potentially underestimate true prevalence of the disease. .In this condition neurons in the brain are not regenerate. It is a disease in which the optic nerve of our eyes which is connected to brain is damage or breakdown. After damaging the optic nerve result is loss of vision partially or completely

## Normal vision



## Glaucoma

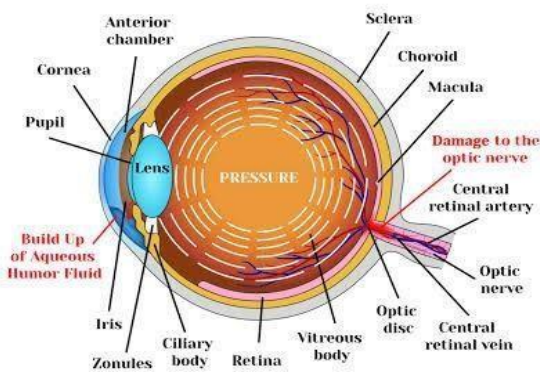


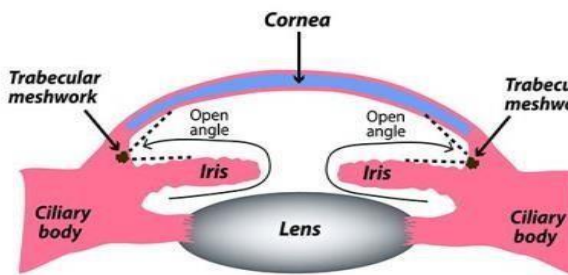
Fig.1 difference between normal vision and glaucoma (8)

### Categories of glaucoma-

- 1) Primary open angle glaucoma
- 2) Primary angle closure glaucoma
- 3) Secondary open angle glaucoma
- 4) Secondary angle closure glaucoma

1. The primary open angle glaucoma is most common in United States.

➤ **Primary open angle glaucoma :-**It can occur with or without elevated ocular hypertension . If eye pressure increase too much then damage the optic nerve and lead to loss of vision permanently.



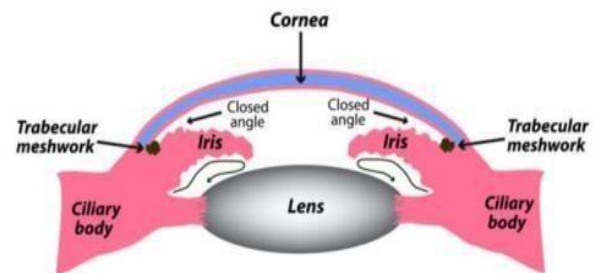
### OPEN-ANGLE GLAUCOMA

Fig.2 open angle glaucoma

➤ Sometimes it is also known as normal tension glaucoma. If These disease occur both adults {after 40 year age} and children {age between 3-40 year}. It does not have Identifiable cause. However, POAG usually responds well to treatment when detected early. Having regular comprehensive eye exams can lead to early detection, which can help prevent vision loss.( 11)

### 2. Primary angle closure glaucoma –

➤ Primary angle-closure glaucoma (PACG) is a chronic optic neuropathy associated with loss of retinal ganglion cells and their axons and typically affects older adults. PACG carries a higher risk of severe visual impairment than chronic open-angle glaucoma. Angle closure is caused by several mechanisms, the most common of which is pupillary block, in which aqueous humor obstructs the flow between the lens and the posterior surface of the iris (up to 75% of cases). Nonpupillary causes of blockage include iris plateau and angle closure caused by the lens (i.e., swelling or instability). (9).



### ANGLE-CLOSURE GLAUCOMA

Fig.3. Primary angle closure glaucoma

### 3. Secondary open angle glaucoma –

➤ Secondary open-angle glaucoma is a heterogeneous group of diseases in which various

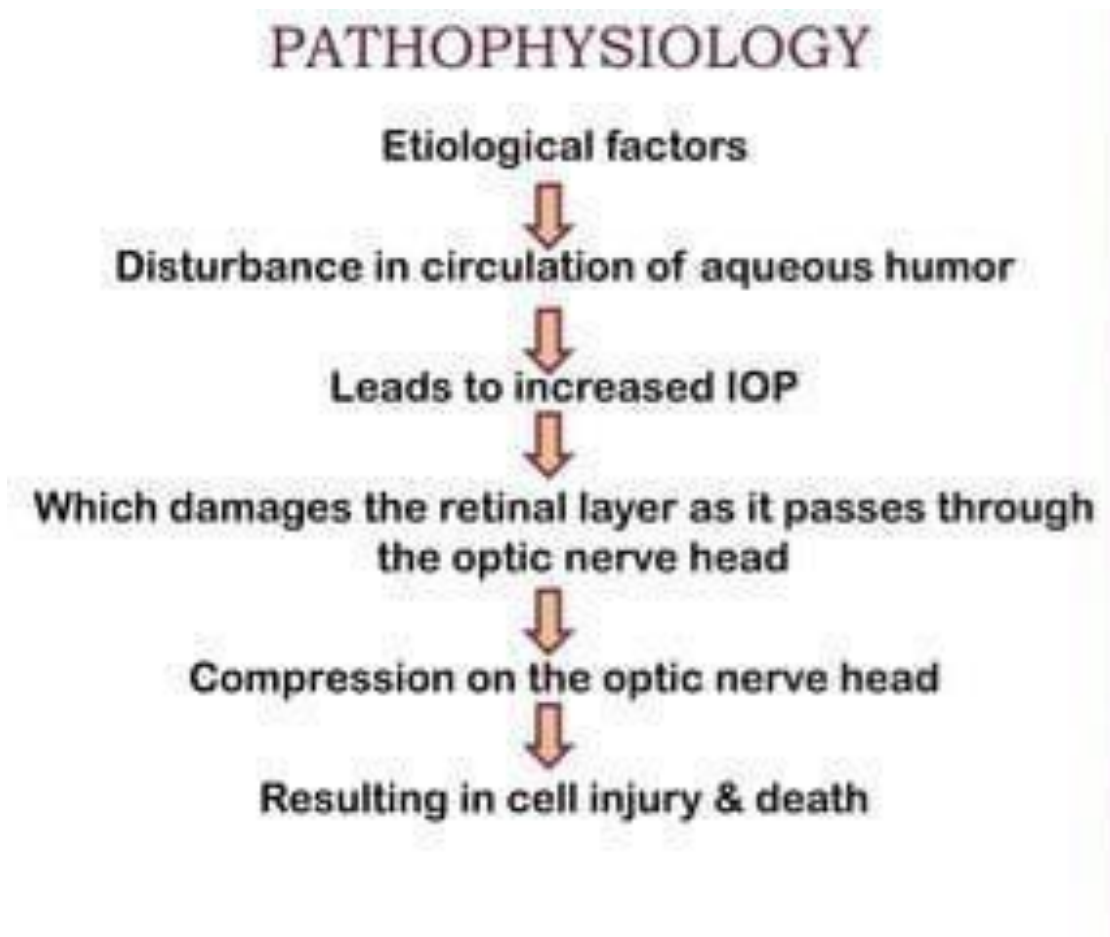
pathophysiological mechanisms lead to increased intraocular pressure.

#### 4. Secondary angle closure glaucoma –

➤ Secondary angle closure is caused by an identifiable pathological etiology, such as: B. Neovascularization or uveitis (see “Differential diagnosis” section). If angle-closure glaucoma leads to an increase in intraocular pressure, which leads to glaucomatous damage to the optic disc, it is called secondary angle-closure [5,6,10,17,18]

#### Pathophysiology –

Although the pathogenesis of glaucoma is not fully understood, the level of intraocular pressure is associated with ganglion cell death. The balance between the secretion of aqueous humor by the ciliary body and its drainage by two independent pathways - the trabecular meshwork and the uveoscleral drainage pathway - determines intraocular pressure. A better understanding of the pathophysiological mechanisms involved in the onset and progression of glaucomatous optic neuropathy is important to develop better therapeutic options.[12,13,16,17]



Filtration depends on pressure gradient, blood pressure and IOP elevation. The osmotic gradient created by the active secretion of sodium ions, bicarbonate, and other solutes creates a pressure gradient that allows fluid to move from the ciliary stromal ultrafiltration tank toward the posterior chamber, thereby creating a translation. Many different receptors and transmitters are found in the ciliary epithelium and smooth muscle structures of the eye. Carbonic anhydrase (mainly type II

isozyme),  $\alpha$ - and  $\beta$ -adrenergic receptors, activated sodium and potassium triphosphates, prostaglandins and muscarinic receptors all play a role in the normal functioning of the eye .

#### Etiology-

1. Increased intraocular pressure.
2. Increased sensitivity of the optic nerve to ischemia.

3. Suppress or interrupted blood flow.
4. Autoimmune reaction.
5. Stimulant toxicity.
6. Abnormal physiological process.
7. Peeling syndrome.
8. Pigmentary glaucoma.
9. Systemic disease.
10. Trauma.
11. Surgery.
12. Goal changes.
13. Drug-induced eye inflammation .
14. Age over 50 .
15. Family history of glaucoma . [12,14]

### Symptoms –

Symptoms of glaucoma depend on the type and stage of your disease.

- 1) Early stages have no symptoms
- 2) Blurred vision
- 3) Gradually, blind spots appear in your side vision. Side vision is also known as peripheral vision
- 4) In the later stages, it is difficult to see things in central vision.[14 ]
- 5) Rapidly progressive vision loss
- 6) Eye pain
- 7) Red eyes
- 8) Nausea, vomiting
- 9) Fear of light
- 10) Transient halos and watermarks indicate previous disruption attacks.

### Diagnosis –

Glaucoma is usually detected during a routine eye exam, often before it causes visible symptoms. After this, further tests are usually required to diagnose and monitor the disease. Regular eye exams are important so that problems like glaucoma can be diagnosed and treated as early as possible. Early treatment can help prevent severe vision deterioration. You should have your eyesight checked at least every 2 years. If you

are at higher risk of glaucoma, for example if you have a close relative, you may be recommended more frequent testing. You can have your eyes examined at your local ophthalmologist and the examination will be performed by an optometrist.

### Tests to diagnose and monitor glaucoma -

There are many different tests that can be performed by an optometrist if they suspect you have glaucoma after a routine eye exam.

#### A) Eye pressure test

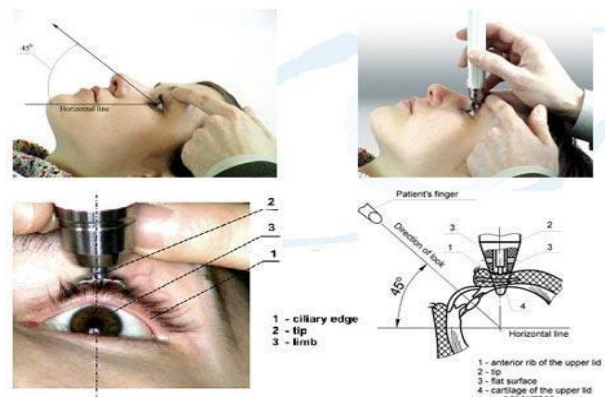


Fig.4 Eye pressure test (22)

Eye pressure test (tonometry) uses an instrument called a tonometer to measure the pressure inside your eye.

The optometrist will apply a small amount of pain medication (anesthesia) and dye to the front of your eye. They will then shine a light into your eye and gently touch the surface of your eye with intraocular pressure.

Some optometrists use a different instrument, which uses a stream of air and does not touch the eye to check the pressure. (20)

#### Eye pressure test at home-

##### The fingertip test-

Very high IOP can be detected with your fingertip. Accuracy will be higher if the examiner is familiar with this test method, so take the time to practice it: first on yourself, then with your colleagues (with their permission).

**Note:** If nothing unusual is detected, eye pressure may remain dangerously high. If the history or symptoms suggest glaucoma, or if the patient is taking steroid medications or has recently had eye



surgery, you should refer them to a center where their IOP can be accurately assessed.

#### Method-

- Ask the patient to close their eyes and look down.
- Place the tips of your index fingers on your closed upper eyelids. Keeping both fingers in contact with the upper eyelid, gently press on the closed eyelid, first gently pressing on the eye with the right index finger, then with the left index finger, then again with the right index finger . Repeat with the other eye.
- Normal eyes will look a bit like a just ripe tomato: neither too hard nor too soft.
- It is important to compare the two eyes. Eyes with very high IOP will be unusually hard and strong. (21)

#### B)Gonioscopy

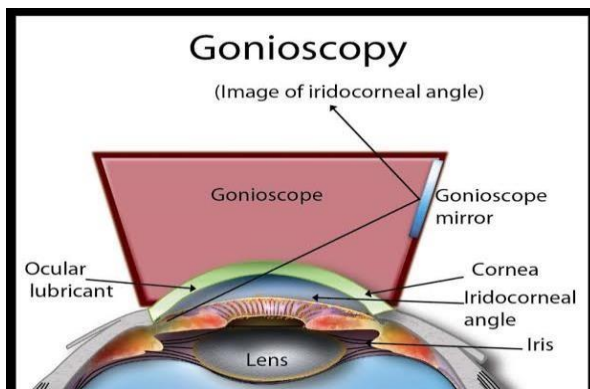


Fig. 5 Gonioscopy (23)

Gonioscopy is a procedure to examine the front part of the eye - the fluid-filled space between the colored part (iris) and the clear window at the front of the eye (cornea). This is where the fluid will drain from your eye.

Gonioscopy can help determine whether this area ("angle") is open or closed (blocked), which can affect how fluid drains from your eye. It will tell your eye doctor what type of glaucoma you have. (20)

#### When should gonioscopy be performed?

The first signs of vision problems and eye diseases can appear around the age of 40. Next, all adults should undergo basic screening for eye diseases by an ophthalmologist

Screening for glaucoma symptoms. Your ophthalmologist will perform a gonioscopy to check the appearance and function of the drainage angle. Some people are suspected of having glaucoma. Your eye pressure may or may not be above normal, but your eye doctor may notice other signs that could indicate you are developing glaucoma. In this case, your eye doctor will regularly perform gonioscopy and other glaucoma screening tests to detect changes over time.

When it comes to eye tracking, time is of the essence. It is important that you keep your scheduled appointments with your eye doctor. Regular check-ups can save your eyesight.(24)

#### Gonioscopy: What to Expect

During a gonioscopy exam, you will have to rest your head on the chin rest of a slit lamp microscope (a special instrument that an ophthalmologist uses to look into your eyes). At this point, your eyes will be numb from the eye drops.

Your ophthalmologist places a special mirrored contact lens directly on your eye. They shine a beam of light into the lens to highlight the drainage angle. Lens mirrors help visualize the part of the eye that is usually in the corner of the eye and is difficult to see.

#### method

1. The doctor will put drops in your eyes to anesthetize the cornea so you do not feel uncomfortable during the procedure.
2. You will be asked to place your chin and forehead in front of the slit lamp to examine the angle.
3. The gonioscopy lens will gently touch your eye and a beam of light will be moved to evaluate the entire circumference of the angle. In some cases, your doctor may carefully press the lens against your cornea to get more information, especially in eyes at risk for narrow-angle glaucoma.

This is a painless procedure and you can help your doctor make a better assessment by holding your forehead and chin steady against the slit lamp, eyes wide open, trying to get used to the contact of the lens with the cornea, trying to Try not to blink and keep looking straight ahead. (25)

**C) Visual Field Test :-**

Visual field testing (sometimes called perimetry) checks for missing visual areas.

You may see a series of bright spots and are asked to press a button to indicate which bright spots you can see. Some spots will appear at the edge of your vision (peripheral vision), which is often the first area affected by glaucoma.

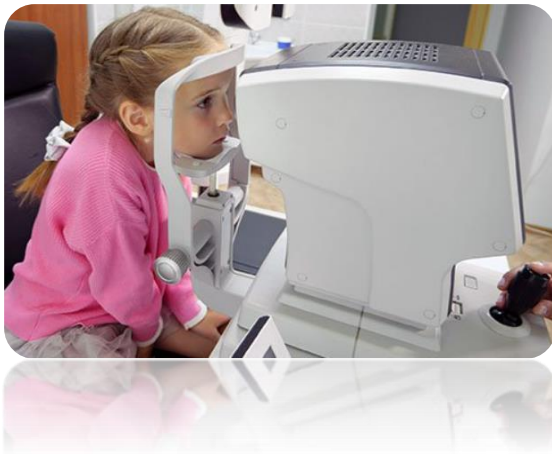

Fig .6. Visual field test(27)

If you can't see spots in the periphery, it means glaucoma has damaged your vision. (20)

**D) Optic nerve assessment -**

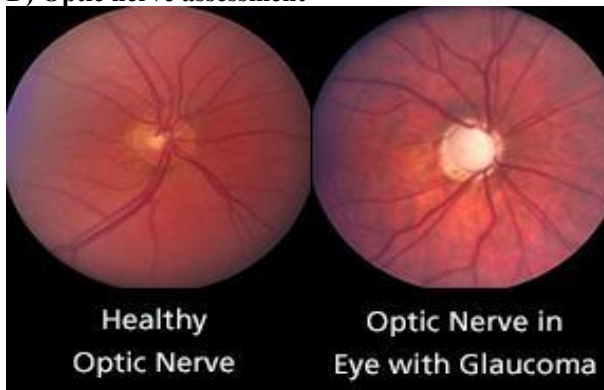


Fig.7. Difference between healthy optic nerve and optic nerve in eye with glaucoma (26)

The optic nerve, which connects your eyes to your brain, can be damaged in glaucoma, so an assessment may be done to see if it is healthy or not.

For the test, you will be given eye drops to enlarge your pupils. Your eyes will then be examined using:  
 -slit lamp (a brightly lit microscope)  
 -optical coherence tomography

- a type of scan in which special light rays are used to scan the back of your eyes and create an image  
 Drops used to widen your pupils may temporarily affect your ability to drive. Therefore, you will need to make arrangements to return home after your appointment.(20)

**E) Referral to a specialist**

If glaucoma is detected during an eye examination, you should be referred to a specialist ophthalmologist (ophthalmologist) for further examination. They will confirm your diagnosis and find out:

**How far the disease has progressed –**

- 1) What damage the glaucoma has caused to your eyes?
  - 2)What can cause glaucoma ?
- Then, they will be able to advise you on treatment. See glaucoma treatment for more information.

In some cases, your ophthalmologist will continue to treat you. But for less severe types of glaucoma, you may be referred to an ophthalmologist. (20)




Fig.8 (28)

**Treatment for glaucoma-**

**Home remedies –**

These tips can help you control high eye pressure and promote eye health.

- **Pay attention to a healthy diet –**  
 A healthy diet can help you stay healthy ,but it wan't prevent your glaucoma from getting worse. Numerous vitamins and nutrients are important for

eye health ,Including zinc , copper , selenium, and anti oxidant vitamin C,E ,A.

- **Exercise safely-**

Regular exercise can lower eye pressure .talk your doctor about an appropriate exercise program.

- **Limit caffeine-**consuming drinks that contain a lot of caffeine can increase eye pressure

- **Drink liquids carefully-** Drink moderate amount of fluids. Drinking a liter or more of fluid in short period of time can temporarily increase eye pressure.

- **Take the medication that has been prescribed for you.**

Using eye drops or other medication as directed can help you achieved the best possible treatment result .Make sure you use the drops exactly as directed. Otherwise ,the damage to the optic nerve may worsen.(19)

#### Natural products used for glaucoma treatment –

##### 1)Ginkgo biloba L.

Ginkgo biloba has been used for hundreds of years to treat a variety of conditions such as asthma, dizziness, fatigue, tinnitus and circulatory problems.(29)

Ginkgo biloba L. (GB) belongs to the Ginkgoaceae family and its leaves and seeds have been used for medicinal purposes for centuries.(30)

With over 70 different flavonoids identified in the UK, they are thought to have broad-spectrum free radical scavenging activity (31). Indeed, treatment with GB extract could increase RGC lineage survival in mice, after exposure to hydrogen peroxide (H<sub>2</sub>O<sub>2</sub>)-induced oxidative stress (32). Additionally, POAG patients treated with 120 mg of GB extract daily for at least 6 months demonstrated a lower incidence of single-strand DNA breaks in circulating leukocytes, Suggesting reduced oxidative stress ( 33).

Ginkgo biloba has been around for over 250 million years and is native to Korea, Japan and China, but is found all over the world. It can reach a height of 40 meters and live more than 1,000 years. Ginkgo biloba leaf extracts have been used for hundreds of years to treat various diseases such as asthma, dizziness, fatigue, tinnitus and circulatory problems (34,35,36).

These extracts consist mainly of flavonoids and terpenoids. Two of the main extracts are EGb761 and LI 1370.Most pharmacological, toxicological and clinical studies have focused on the neuroprotective value of these two main extracts (37,38,39)

Neuroprotection is a dynamically developing field of research. This area is particularly interesting as it represents a new therapeutic avenue for a frustrating disease that can progress despite optimal treatment. One of these diseases is glaucoma.



Fig.9. Ginkgo biloba L.(27)

Glaucoma causes loss of retinal ganglion cells and their axons, but also tissue remodeling that affects both the optic nerve head and the retina .Astrocytes are activated in the retina. In addition, the optic nerve becomes thinner and the cells of the lateral geniculate ganglion partially disappear . In glaucoma patients, on average, blood flow to the various tissues of the eye is reduced. The reduction in blood flow is more clearly visible in normal-tension glaucoma (NTG) than in high-tension glaucoma (HTG) and comparatively more clearly visible in patients with progressive glaucoma than in patients with stable glaucoma.(40,41,42)

##### 2)Coleus forskohlii (willd.) Briq.—Forskolin

Coleus forskohlii (willd.) Briq. It is a medicinal plant native to India and Southeast Asia(44). The leaves, roots and tubers of C. forskohlii are a rich source of a diterpenoid called forskolin, which acts as a second messenger, an activator of cyclic adenosine 3',5'-monophosphate (cAMP), through direct stimulation of adenylate cyclase.(45).Studies have shown that cAMP plays an important role in regulating aqueous humor dynamics in the ciliary body and MT (46). In fact, a previous study showed that intra-arterial forskolin at doses of 30, 100, and 1000 nm resulted in a significant reduction in the rate of aqueous humor formation in an isolated bovine eye preparation (47). This could explain the antihypertensive effect of forskolin administration, as demonstrated in a double-blind, randomized, controlled trial in which patients with



POAG were treated with 1% w/v aqueous forskolin eye drops at a dose of two drops three times per day for 4 days. weeks there was a significant decrease in intraocular pressure (47,48).



**Fig.10. Forsydia speciosa**

### 3) *Curcuma longa L.*—Curcumin

Curcumin is a yellow pigment and the active ingredient of the rhizome of *Curcuma longa L.*, i.e. turmeric (49). It is known for its antioxidant, anti-inflammatory, antitumor, antiarthritic, anti asthmatic, antimicrobial, antiviral and antifungal properties (50,51). Since curcumin is a powerful natural antioxidant, it could represent another potential treatment for alleviating the oxidative stress associated with glaucoma. Recent research from University College London and Imperial College London in the United Kingdom suggests that a turmeric derivative, curcumin, may be effective in treating the early symptoms of glaucoma. Additionally, researchers are finding that there is an effective method by which curcumin can be administered directly into the back of the eye via eye drops. This turmeric derivative is known to be poorly soluble, but a new technique developed by the team will allow specialists to solve this problem.(52)



**Fig.11 curcuma longa L.**

### 4) Caffeine

Caffeine (1, 3, 7-trimethylxanthine) is a natural alkaloid commonly consumed in coffee, tea, soft drinks, energy drinks, chocolate and other cocoa-containing foods (53). Caffeine has a stimulating effect on the central nervous system due to its antagonistic properties against adenosine A1 and A2a receptors (53). The literature indicates that the effect of caffeine consumption on intraocular pressure is controversial. Tran et al. (54) showed a reduction in intraocular pressure after 45 and 60 minutes of caffeine consumption in patients with POAG compared to the water drinking group. However, another study showed that 1-caffeine eye drops administered daily for a week had no effect on intraocular pressure in patients with POAG(55).



**Fig.12. Caffeine (56)**

### 5) Panax Ginseng – Ginsenoside

Panax Ginseng from the Araliaceae family is considered one of the most commonly used medicinal herbs and functional foods (57,58). In a randomized, placebo-controlled, crossover study, daily consumption of 3 g of Korean red ginseng (KRG) for 4 weeks was shown to improve daytime



contrast sensitivity and ocular pain in glaucoma patients (59). After 8 weeks of KRG supplementation in glaucoma patients, significant improvements in tear film stability and total ocular surface disease score of were demonstrated, suggesting that KRG alleviates dry eye symptoms in glaucoma patients. Glaucoma (60). Furthermore, patients with OAG who received 1.5 g KRG orally three times daily for 12 weeks showed significant improvement in retinal blood flow in the temporal peripapillary area (61).



Fig.13.panax Ginseng (62)

#### 6)Resveratrol

Resveratrol (trans-3,4',5-trihydroxystilbene) is a polyphenol found in berries, grapes, pomegranates and red wine (63). It has been reported to have a wide range of pharmacological effects, including cardioprotective, neuroprotective, and antidiabetic effects due to its potent antioxidant and anti-inflammatory properties (63).



Fig.14 Resveratrol

Resveratrol has been reported to increase oxidative stress markers and nitric oxide levels in human glaucoma TM cells, possibly by increasing the expression of endothelial nitric oxide synthase (eNOS) and decreasing the inducible expression of NOS (64). In experimental glaucoma models, treatment with resveratrol has been shown to reduce the risk of death from RGC (65,66). Cao et al.(66) also showed that intravitreal administration of resveratrol rescued RGCs by decreasing ROS production in RGCs in a mouse model of bead-induced increased intraocular pressure. These studies provide evidence of resveratrol's antioxidant properties, which could be useful in treating glaucoma. Resveratrol protects RGC-5 cells from H<sub>2</sub>O<sub>2</sub>-induced apoptosis by inhibiting H<sub>2</sub>O<sub>2</sub>-induced increased expression of cleaved caspase-3/-9, ROS production and expression of p-p38, p-ERK and p- JNK reverses, suggesting resveratrol inhibits MAPK cascades to exert neuroprotective effects in RGCs (67). In addition, retinal I/R injury-induced RGC loss, glial activation, and impaired retinal function also ameliorates resveratrol by inhibiting the HIF-1 $\alpha$ /VEGF and p38/p53 signaling pathways and concomitantly inhibiting PI3K/AKT activated(68,69,70).

#### Reference -

- [1]. (N.d.). Ieee.org. Retrieved October 23, 2023, from <https://ieeexplore.ieee.org/document/9360745>
- [2]. Shalaby, Wesam Shamseldin , Osama M. Ahmed, Michael Waisbourd, and L. Jay Katz. "A review of potential novel glaucoma therapeutic options independent of intraocular pressure." *Survey of Ophthalmology* 67, no. 4 (2022): 1062-1080.
- [3]. (N.d.-b). Researchgate.net. Retrieved October 23, 2023, from <https://www.researchgate.net/publication/282792352v>
- [4]. Boyd, K. (2022, December 6). What is glaucoma? Symptoms, causes, diagnosis, treatment. *American Academy of Ophthalmology*. <https://www.aao.org/eye-health/diseases/what-is-glaucoma>
- [5]. Glaucoma: An introduction. (n.d.). *TheraSpecs*. Retrieved October 23, 2023, from <https://www.theraspecs.com/blog/glaucoma-an-introduction>
- [6]. Dietze, J., Blair, K., & Havens, S. J. (2022). *Glaucoma*. StatPearls Publishing.
- [7]. What is primary open angle glaucoma (POAG)? (n.d.). *All About Vision*. Retrieved

- October 23, 2023, from <https://www.allaboutvision.com/conditions/primary-open-angle-glaucoma>
- [8]. No title. (n.d.). Goo.Gl. Retrieved October 23, 2023, from <https://images.app.goo.gl/21MEchA5UDPuQnmo6>
- [9]. (N.d.). College-optometrists.org. Retrieved October 23, 2023, from [https://www.college-optometrists.org/clinical-guidance/clinical-managementguidelines/primaryangleclosure\\_primaryangleclosureglaucoma\\_pa](https://www.college-optometrists.org/clinical-guidance/clinical-managementguidelines/primaryangleclosure_primaryangleclosureglaucoma_pa)
- [10]. Greslechner, R., Helbig, H., & Spiegel, D. (2022). Sekundäre Offenwinkelglaukome: Pseudoexfoliationsglaukom, Pigmentglaukom und Neovaskularisationsglaukom. *Der Ophthalmologic: Zeitschrift der Deutschen Ophthalmologischen Gesellschaft*, 119(4), 425–438. <https://doi.org/10.1007/s00347-022-01609-3>
- [11]. Primary vs. Secondary angle closure glaucoma - EyeWiki. (2023, October 1). Aao.org. [https://eyewiki.aao.org/Primary\\_vs.\\_Secondary\\_Angle\\_Closure\\_Glaucoma](https://eyewiki.aao.org/Primary_vs._Secondary_Angle_Closure_Glaucoma)
- [12]. (N.d.-c). Ijcert.org. Retrieved October 23, 2023, from <https://ijcert.org/papers/IJCRT2308586.pdf>
- [13]. Weinreb, Robert N., et al. “The Pathophysiology and Treatment of Glaucoma: A Review.” *JAMA: The Journal of the American Medical Association*, vol. 311, no. 18, 2014, p. 1901, doi:10.1001/jama.2014.3192.
- [14]. Glaucoma. (2022, September 30). Mayo Clinic. <https://www.mayoclinic.org/diseases-conditions/glaucoma/symptoms-causes/syc-20372839>
- [15]. Ko F. Papadopoulos M, Khaw PT. Primary congenital glaucoma. *Prog Brain Res* 2015; 221: 177183.
- [16]. Quigley HA, Katz J, Derick RJ, Gilbert D, Sommer A. An evaluation of optic disc and nerve fiber layer examinations in monitoring progression of early Ophthalmology 2013; 120: 535-543.
- [17]. Before you continue. (n.d.). Google.com. Retrieved October 24, 2023, from <https://www.google.com/imgres?imgurl=https%3A%2F%2Fimages.cfassets.net%2Fu4vv676b8z>
- [18]. No title. (n.d.-b). Goo.Gl. Retrieved October 24, 2023, from <https://images.app.goo.gl/EhKS44G2vV2PRKky6>
- [19]. <https://www.mayoclinic.org/diseases-conditions/glaucoma/diagnosis-treatment/drc-20372846>
- [20]. ---. “The Pathophysiology and Treatment of Glaucoma: A Review.” *JAMA: The Journal of the American Medical Association*, vol. 311, no. 18, 2014, p. 1901, doi:10.1001/jama.2014.3192.
- [21]. “Glaucoma – Diagnosis.” Nhs.uk, <https://www.nhs.uk/conditions/glaucoma/diagnosis/>. Accessed 25 Oct. 2023.
- [22]. Wolvaardt, Elmien, and Sue Stevens. “Measuring Intraocular Pressure.” *Community Eye Health*, vol. 32, no. 107, 2019, pp. 56–57.
- [23]. Before You Continue.” Google.com, <https://www.google.com/imgres?imgurl=https://www.eyedoctorophthalmologistnyc.com/wp-content/uploads/2016/10/Eye-Pressure-Test-Tonometry-NYC.jpg&tbid=151D5hm1uMp0AM&vet=1&imgrefurl=https://www.eyedoctorophthalmologistnyc.com/procedures/eye-pressure-test-tonometry/&docid=2GPCfwC6suupTM&w=468&h=351&hl=en-US&source=sh/x/im/can/2&shem=uvafe2&sf r=vfe>. Accessed 25 Oct. 2023.
- [24]. “---.” Google.com, [https://www.google.com/imgres?imgurl=https://lookaside.fb.com/lookaside/crawler/media/?media\\_id%3D151194003291499&tbid=dHbz8Kiu8RTfPM&vet=1&imgrefurl=https://m.facebook.com/futureinoptometry/photos/a.108282787582621/151194003291499/?type%3D3&docid=iUVE-C2G96UMnM&w=1258&h=1008&itg=1&hl=en-US&source=sh/x/im/can/2&shem=uvafe2&sf r=vfe](https://www.google.com/imgres?imgurl=https://lookaside.fb.com/lookaside/crawler/media/?media_id%3D151194003291499&tbid=dHbz8Kiu8RTfPM&vet=1&imgrefurl=https://m.facebook.com/futureinoptometry/photos/a.108282787582621/151194003291499/?type%3D3&docid=iUVE-C2G96UMnM&w=1258&h=1008&itg=1&hl=en-US&source=sh/x/im/can/2&shem=uvafe2&sf r=vfe). Accessed 25 Oct. 2023.
- [25]. Boyd, Kierstan. “What Is Gonioscopy?” *American Academy of Ophthalmology*, 27 Mar. 2019, <https://www.aao.org/eye-health/treatments/what-is-gonioscopy>.
- [26]. willem3bergen. “How Is Gonioscopy Done?” *Glaucoma Information, World Glaucoma Association*, 8 Mar. 2018, <https://www.glaucomapatient.org/examination/how-is-gonioscopy-done/>.
- [27]. “---.” Google.com, <https://www.google.com/imgres?imgurl=https://earimediaproductweb.azurewebsites.net/Api/v>

- 1/Multimedia/1eab733b-642e-4562-83c7-70169623ce0f/Rendition/low-res/Content/Public&tbnid=EM6Y9t7uXcYKEM&vet=1&imgrefurl=https://www.eurekalert.org/pub\_releases/2018-11/cu-tgt110818.php&docid=yEIH0qu1SbMslM&w=290&h=200&hl=en-US&source=sh/x/im/can/2&shem=uvafe2&sr=vfe. Accessed 25 Oct. 2023.
- [28]. “---.” Goo.Gl, <https://images.app.goo.gl/F3WuFdDPtkGMyHNE8>. Accessed 25 Oct. 2023.
- [29]. “---.” Google.com, <https://www.google.com/imgres?imgurl=https://www.smilelasermultan.com/wp-content/uploads/2021/06/Glaucoma-Tests-867x1024-1.jpg&tbnid=TJN0AnO7U8MZ6M&vet=1&imgrefurl=https://www.smilelasermultan.com/visual-field-test/&docid=jq4UUi7H2P1txM&w=867&h=1024&hl=en-US&source=sh/x/im/m1/4&shem=uvafe2>. Accessed 25 Oct. 2023.
- [30]. Cybulska-Heinrich, A. K., et al. “Ginkgo Biloba: An Adjuvant Therapy for Progressive Normal and High Tension Glaucoma.” *Molecular Vision*, vol. 18, 2012, pp. 390–402.
- [31]. Achete de Souza G., de Marqui S.V., Matias J.N., Guiguer E.L., Barbalho S.M. Effects of Ginkgo biloba on diseases related to oxidative stress. *Planta Med.* 2020;86:376–386. doi: 10.1055/a-1109-3405. [PubMed] [CrossRef] [Google Scholar]
- [32]. Liu X.G., Wu S.Q., Li P., Yang H. Advancement in the chemical analysis and quality control of flavonoid in Ginkgo biloba. *J. Pharm. Biomed. Anal.* 2015;113:212–225. doi: 10.1016/j.jpba.2015.03.006. [PubMed] [CrossRef] [Google Scholar]
- [33]. Cho H.K., Kim S., Lee E.J., Kee C. Neuroprotective effect of Ginkgo biloba extract against hypoxic retinal ganglion cell degeneration in vitro and in vivo. *J. Med. Food.* 2019;22:771–778. doi: 10.1089/jmf.2018.4350. [PubMed] [CrossRef] [Google Scholar]
- [34]. Fang L., Neutzner A., Turtschi S., Flammer J., Mozaffarieh M. The effect of Ginkgo biloba and Nifedipine on DNA breaks in circulating leukocytes of glaucoma patients. *Expert Rev. Ophthalmol.* 2015;10:313–318. doi: 10.1586/17469899.2015.1043994. [CrossRef] [Google Scholar]
- [35]. Bachinskaya N, Hoerr R, Ihl R. Alleviating neuropsychiatric symptoms in dementia: the effects of Ginkgo biloba extract EGb 761. Findings from a randomized controlled trial. *Neuropsychiatr Dis Treat.* 2011;7:209–15. [PMC free article] [PubMed] [Google Scholar]
- [36]. Li S, Tang D, Xue Z, Zhang Z, Sun X, Liu Y, Dong H, Yin X, Zhang Z. Biphasic effect of EGb761 on simulated ischemia-induced rat BMSC survival in vitro and in vivo. *Life Sci.* 2011;88:853–63. [PubMed] [Google Scholar]
- [37]. Janssen IM, Sturtz S, Skipka G, Zentner A, Garrido MV, Busse R. Ginkgo biloba in Alzheimer's disease: a systematic review. *Wien Med Wochenschr.* 2010;160:539–46. [PubMed] [Google Scholar]
- [38]. de Lima KC, Schiliching CL, Junior LA, da Silva FM, Benetoli A, Milani H. The Ginkgo biloba extract, EGb 761, fails to reduce brain infarct size in rats after transient, middle cerebral artery occlusion in conditions of unprevented, ischemia-induced fever. *Phytother Res.* 2006;20:438–43. [PubMed] [Google Scholar]
- [39]. Shah ZA, Nada SE, Dore S. Heme oxygenase 1, beneficial role in permanent ischemic stroke and in Ginkgo biloba (EGb 761) neuroprotection. *Neuroscience.* 2011;180:248–55. [PMC free article] [PubMed] [Google Scholar]
- [40]. Chung SY, Cheng FC, Lee MS, Lin JY, Lin MC, Wang MF. Ginkgo biloba leaf extract (EGb761) combined with neuroprotective agents reduces the infarct volumes of gerbil ischemic brain. *Am J Chin Med.* 2006;34:803–17. [PubMed] [Google Scholar]
- [41]. Ritch R. Neuroprotection: is it already applicable to glaucoma therapy? *Curr Opin Ophthalmol.* 2000;11:78–84. [PubMed] [Google Scholar]
- [42]. Flammer J. *Glaucoma a guide for patients an introduction for care-providers a reference for quick information.* Bern: Hans Huber; 2001. [Google Scholar]
- [43]. Flammer J, Orgul S, Costa VP, Orzalesi N, Kriegstein GK, Serra LM, Renard JP, Stefansson E. The impact of ocular blood flow in glaucoma. *Prog Retin Eye Res.* 2002;21:359–93. [PubMed] [Google Scholar]

- [44]. No title, n.d.) No title. (n.d.). Goo.Gl. Retrieved November 20, 2023, from <https://images.app.goo.gl/JuCBPLMNtRKT5HyF6>
- [45]. Srivastava S., Misra A., Mishra P., Shukla P., Kumar M., Sundaresan V., Negi K.S., Agrawal P.K., Rawat A.K.S. Molecular and chemotypic variability of forskolin in *Coleus forskohlii* Briq., a high value industrial crop collected from Western Himalayas (India) RSC Adv. 2017;7:8843–8851. Doi: 10.1039/C6RA26190F. [CrossRef] [Google Scholar]
- [46]. Shim M.S., Kim K.Y., Ju W.K. Role of cyclic AMP in the eye with glaucoma. BMB Rep. 2017;50:60–70. Doi: 10.5483/BMBRep.2017.50.2.200. [PMC free article] [PubMed] [CrossRef] [Google Scholar]
- [47]. Shahidullah M., Wilson W.S., Rafiq K., Sikder M.H., Ferdous J., Delamere N.A. Terbutaline, forskolin and cAMP reduce secretion of aqueous humour in the isolated bovine eye. PLoS ONE. 2020;15:e0244253. Doi: 10.1371/journal.pone.0244253. [PMC free article] [PubMed] [CrossRef] [Google Scholar]
- [48]. Majeed M., Nagabhushanam K., Natarajan S., Vaidyanathan P., Kumar S.K. A double-blind, randomized clinical trial to evaluate the efficacy and safety of forskolin eye drops 1% in the treatment of open angle glaucoma—A comparative study. J. Clin. Trials. 2014;4:1000184. Doi: 10.4172/2167-0870.1000184. [CrossRef] [Google Scholar]
- [49]. Majeed M., Nagabhushanam K., Natarajan S., Vaidyanathan P., Karri S.K., Jose J.A. Efficacy and safety of 1% forskolin eye drops in open angle glaucoma—An open label study. Saudi J. Ophthalmol. 2015;29:197–200. Doi: 10.1016/j.sjopt.2015.02.003. [PMC free article] [PubMed] [CrossRef] [Google Scholar]
- [50]. Kevin T.T.M., Nur Idanis A.S., Anastasha B., Mohd Faris M.R., Faizah O., Taty Anna K. Curcumin minimises histopathological and immunological progression in the ankle joints of collagen-induced arthritis rats. Med. Health. 2020;15:26–36. Doi: 10.17576/MH.2020.1502.05. [CrossRef] [Google Scholar]
- [51]. Kamal D.A.M., Salamt N., Yusuf A.N.M., Kashim M., Mokhtar M.H. Potential health benefits of curcumin on female reproductive disorders: A review. Nutrients. 2021;13:3126. Doi: 10.3390/nu13093126. [PMC free article] [PubMed] [CrossRef] [Google Scholar]
- [52]. Yue Y.K., Mo B., Zhao J., Yu Y.J., Liu L., Yue C.L., Liu W. Neuroprotective effect of curcumin against oxidative damage in BV-2 microglia and high intraocular pressure animal model. J. Ocul. Pharmacol. Ther. 2014;30:657–664. Doi: 10.1089/jop.2014.0022. [PubMed] [CrossRef] [Google Scholar]
- [53]. (Cohut, 2018) Cohut, M. (2018, July 25). How a turmeric compound could treat glaucoma. Medical News Today. <https://www.medicalnewstoday.com/articles/322573>
- [54]. Md Isa Z., Anuar A.A., Danial Azmi A., Selvan S.T., Hisham N.S., Yong Z.Q. Does caffeine intake influence mental health of medical students? Malays. J. Public Health Med. 2021;21:22–28. Doi: 10.37268/mjphm/vol.21/no.2/art.626. [CrossRef] [Google Scholar]
- [55]. Tran T., Niyadurupola N., O'Connor J., Ang G.S., Crowston J., Nguyen D. Rise of intraocular pressure in a caffeine test versus the water drinking test in patients with glaucoma. Clin. Exp. Ophthalmol. 2014;42:427–432. Doi: 10.1111/ceo.12259. [PubMed] [CrossRef] [Google Scholar]
- [56]. Chandra P., Gaur A., Varma S. Effect of caffeine on the intraocular pressure in patients with primary open angle glaucoma. Clin. Ophthalmol. 2011;5:1623–1629. Doi: 10.2147/OPTH.S25291. [PMC free article] [PubMed] [CrossRef] [Google Scholar]
- [57]. (No title, n.d.-b) No title. (n.d.-b). Goo.Gl. Retrieved November 20, 2023, from <https://images.app.goo.gl/bHs2C4uoFtSaEGqL7>
- [58]. Patel S., Rauf A. Adaptogenic herb ginseng (*Panax*) as medical food: Status quo and future prospects. Biomed. Pharmacother. 2017;85:120–127. doi: 10.1016/j.biopha.2016.11.112. [PubMed] [CrossRef] [Google Scholar]
- [59]. Kang J.Y., Kim D.Y., Lee J.S., Hwang S.J., Kim G.H., Hyun S.H., Son C.G. Korean red ginseng ameliorates fatigue via modulation of 5-HT and corticosterone in a sleep-deprived mouse model. Nutrients. 2021;13:3121. doi: 10.3390/nu13093121. [PMC free



- article] [PubMed] [CrossRef] [Google Scholar]
- [60]. Lee K., Yang H., Kim J.Y., Choi W., Seong G.J., Kim C.Y., Lee J.M., Bae H.W. Effect of red ginseng on visual function and vision-related quality of life in patients with glaucoma. *J. Ginseng Res.* 2021;45:676–682. doi: 10.1016/j.jgr.2021.03.004. [PMC free article] [PubMed] [CrossRef] [Google Scholar]
- [61]. Bae H.W., Kim J.H., Kim S., Kim M., Lee N., Hong S., Seong G.J., Kim C.Y. Effect of Korean red ginseng supplementation on dry eye syndrome in glaucoma patients—A randomized, double-blind, placebo-controlled study. *J. Ginseng Res.* 2015;39:7–13. doi: 10.1016/j.jgr.2014.07.002. [PMC free article] [PubMed] [CrossRef] [Google Scholar]
- [62]. Kim N.R., Kim J.H., Kim C.Y. Effect of Korean red ginseng supplementation on ocular blood flow in patients with glaucoma. *J. Ginseng Res.* 2010;34:237–245. doi: 10.5142/jgr.2010.34.3.237. [CrossRef] [Google Scholar]
- [63]. [https://www.google.com/imgres?imgurl=https%3A%2F%2Fmedia.springernature.com%2F1w685%2Fspringer-static%2Fimage%2Fart%253A10.1186%252Fs12951-021-01062-5%2FMediaObjects%2F12951\\_2021\\_1062\\_Fig1\\_HTML.png&tbid=FjKgRtPLLZtJJM&vet=1&imgrefurl=https%3A%2F%2Fjnanobio.technology.biomedcentral.com%2Farticles%2F10.1186%2Fs12951-021-01062-5&docid=PAPtFVakd5zxLM&w=685&h=594&hl=en-IN&source=sh%2Fx%2Fim%2Fm1%2F4210](https://www.google.com/imgres?imgurl=https%3A%2F%2Fmedia.springernature.com%2F1w685%2Fspringer-static%2Fimage%2Fart%253A10.1186%252Fs12951-021-01062-5%2FMediaObjects%2F12951_2021_1062_Fig1_HTML.png&tbid=FjKgRtPLLZtJJM&vet=1&imgrefurl=https%3A%2F%2Fjnanobio.technology.biomedcentral.com%2Farticles%2F10.1186%2Fs12951-021-01062-5&docid=PAPtFVakd5zxLM&w=685&h=594&hl=en-IN&source=sh%2Fx%2Fim%2Fm1%2F4210). Ramalingam A., Santhanathas T., Shaikat Ali S., Zainalabidin S. Resveratrol supplementation protects against nicotine-induced kidney injury. *Int. J. Environ. Res Public Health.* 2019;16:4445. doi: 10.3390/ijerph16224445. [PMC free article] [PubMed] [CrossRef] [Google Scholar]
- [65]. Avotri S., Eatman D., Russell-Randall K. Effects of Resveratrol on inflammatory biomarkers in glaucomatous human trabecular meshwork cells. *Nutrients.* 2019;11:984. doi: 10.3390/nu11050984. [PMC free article] [PubMed] [CrossRef] [Google Scholar]
- [66]. Pirhan D., Yuksel N., Emre E., Cengiz A., Kursat Yildiz D. Riluzole- and resveratrol-induced delay of retinal ganglion cell death in an experimental model of glaucoma. *Curr. Eye Res.* 2016;41:59–69. doi: 10.3109/02713683.2015.1004719. [PubMed] [CrossRef] [Google Scholar]
- [67]. Cao K., Ishida T., Fang Y., Shinohara K., Li X., Nagaoka N., Ohno-Matsui K., Yoshida T. Protection of the retinal ganglion cells: Intravitreal injection of resveratrol in mouse model of ocular hypertension. *Investig. Ophthalmol. Vis. Sci.* 2020;61:13. doi: 10.1167/iovs.61.3.13. [PMC free article] [PubMed] [CrossRef] [Google Scholar]
- [68]. Ye M.J., Meng N. Resveratrol acts via the mitogen-activated protein kinase (MAPK) pathway to protect retinal ganglion cells from apoptosis induced by hydrogen peroxide. *Bioengineered.* 2021;12:4878–4886. doi: 10.1080/21655979.2021.1954742. [PMC free article] [PubMed] [CrossRef] [Google Scholar]
- [69]. Ji K., Li Z., Lei Y., Xu W., Ouyang L., He T., Xing Y. Resveratrol attenuates retinal ganglion cell loss in a mouse model of retinal ischemia reperfusion injury via multiple pathways. *Exp. Eye Res.* 2021;209:108683. doi: 10.1016/j.exer.2021.108683. [PubMed] [CrossRef] [Google Scholar]
- [70]. Luo H., Zhuang J., Hu P., Ye W., Chen S., Pang Y., Li N., Deng C., Zhang X. Resveratrol delays retinal ganglion cell loss and attenuates gliosis-related inflammation from ischemia-reperfusion injury. *Investig. Ophthalmol. Vis. Sci.* 2018;59:3879–3888. doi: 10.1167/iovs.18-23806. [PubMed] [CrossRef] [Google Scholar]
- [71]. Xia J., Yang X., Chen W. Resveratrol protects the retina from I/R injury by inhibiting RGCS apoptosis, glial activation and expression of inflammatory factors. *Trop. J. Pharm. Res.* 2020;19:1221–1226. doi: 10.4314/tjpr.v19i6.16. [CrossRef] [Google Scholar]